

## MANAGEMENT OF REFRACTORY PEPTIC OESOPHAGEAL STRICTURES USING A NOVEL EGIS STENT



**Author:** Dr .Mayur Kumar, Consultant Gastroenterologist

**Institute(s):** Princess Royal University Hospital, King's College Hospital NHS Trust, Department of Gastroenterology, London, United Kingdom

**Introduction:** Refractory benign oesophageal strictures often present a challenge to manage. Refractory benign oesophageal strictures (RBOS), as defined by Kochman <sup>1</sup> is a failure to maintain patency of oesophageal lumen after dilatation to 14mm over five sessions performed at two-week intervals. Current UK <sup>1</sup> and European guidance <sup>2</sup> recommend dilatation as first line of therapy for benign oesophageal strictures. Recently metal FCSEMS have been increasingly used to treat refractory benign oesophageal strictures

We describe 2 cases of benign RBOS where we successfully used a nitinol woven (as opposed to braided) stent with double stepped shoulders (designed to prevent stent migration) and an extra ePTFE membrane (EGIS; S&G Biotech, Seoul, Korea). The stent contains proximal and distal removal strings allowing the stent to peel away from the oesophagus with reduced shearing forces on the surrounding tissue.

**Case 1:** 72 year old male patient , presenting with dysphagia for solids, had a 5 cm long refractory peptic stricture not responding to standard CRE balloon dilatations, following which we treated with a 9 cm/18m EGIS FCSEMS across the stricture. Stent left in situ for 8 weeks

**Case 2:** 55 year old male patient had an unusual, long 10 cm smooth stricture/ narrowing of oesophagus as demonstrated on barium study (barium pic?) .Stricture was impassable with a standard gastroscop. A 15cm/18 mm long, fully covered EGIS stent was inserted across the stricture. Stent left in situ for 8 weeks.

Histology from the above strictures confirmed features of severe chronic inflammation but no dysplasia, malignancy or evidence of eosinophilic oesophagitis.

**Results:** Both these stents were removed 8 weeks after insertion. The previously seen refractory strictures resolved completely, allowing passage of a standard gastroscop easily. There was also evidence of oesophageal remodelling. There were no complications reported . Patients were able to eat normal diet following stent removal and structures did not recur at 8 monthly and 10 follow up respectively.

**Conclusions:** Both European and UK guidelines weakly recommend temporary placement of FCSEMS for refractory benign structures. The novel double stepped, double membraned EGIS stents can be successfully used to treat benign refractory oesophageal peptic strictures and cause oesophageal remodelling without any complications such as stent migration or ingrowth.

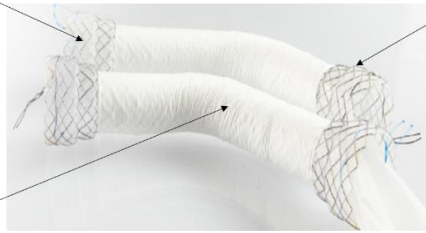
**1. Nitinol woven design**

The knitted design generates a lower axial force, resulting in better conformity to torturous anatomy. This therefore reduced pain and foreign body sensation.

**2. Polytetrafluoroethylene membrane (ePTFE)**

The ePTFE membrane is highly resistant to gastric fluid and, due to its external site, detachment of this membrane is less likely to occur

# EGIS Stent



**3. 'Double-stepped' shoulders**

Reduces the rate of stent migration

**4. Proximal and distal removal strings**

Traction of the lower string inverts the distal end, allowing the stent to be peeled away from the oesophagus. This reduced the shearing forces on the adjacent tissues

**Index OGD- tight stricture**

**EGIS stent across the stricture**

**Stricture resolution at 8 weeks**

